

CHAPTER VII.

LINEAR SERIES—*continued.*

BRANCHIAL OPENINGS OF CHORDATA AND STRUCTURES IN CONNEXION WITH THEM.

UNDER the general heading of Variation of branchial openings facts will be given relating to the following subjects.

I. Variation in the patterns formed by the bars, vessels and stigmata of the branchial sac in Ascidiæ.

II. Variation in the number of gill-sacs in Cyclostomi.

III. Abnormal openings in the cervical region of Mammals, known as "cervical fistulæ," and external appendages called "cervical auricles," or "supernumerary ears," present sometimes in connexion with such openings.

With reference to the two first subjects the evidence is only fragmentary, but the instances recorded seem to be of sufficient consequence to warrant their introduction in illustration especially of the magnitude and definiteness of Variation.

Variations affecting the opercular opening in Amphibia are mentioned in connexion with Bilateral Series.

I. ASCIDIANS.

Transverse vessels of Branchial Sac.

132. **Ascidia scabra.** Branchial sac in one specimen shewing abnormal and irregular structure owing to branching of transverse vessels. The resulting appearance is entirely peculiar. HERDMAN, W. A., *J. Linn. Soc. (Zool.)*, 1881, xv., p. 284, Pl. xvii., fig. 3; also p. 330.
133. **Ascidia virginea** (O. F. Müller): a case of great irregularity exactly similar to the above. *Ibid.*, p. 330.
134. **Ctenicella lanceplani.** Branchial sac may present characters due to variations in disposition of transverse vessels &c., which assume three distinct patterns or marked varieties. LACAZE-DUTHIERS, *Arch. Zool. Exp.*, S. 1, Vol. vi., p. 619, Vol. xxxiii., figs. 9—11.

- *135. **Ascidia plebeia** (Alder): branchial sac has very characteristic appearance and is very constant in the size of meshes, papillæ &c. One point is liable to variation: as a rule the transverse vessels are of the same calibre, but in several specimens every fourth vessel is much wider than the intervening three. HERDMAN, p. 331.

Stigmata and Meshes.

136. **Ciona intestinalis**: meshes vary but according to no apparent method: 5 stigmata in a mesh normal; 4 and 6 met with frequently; 10 the utmost seen. HERDMAN, p. 332.
137. **Ascidia aspersa**. In typical specimens, transverse vessels all same size, the meshes being square and undivided, but individuals occur in which many (not all) of these square meshes are divided by delicate transverse vessels into pairs of oblong areas. HERDMAN, p. 332.
138. **Styela grossularia**. The genus *Styela* is characterized by the presence of branchial folds, normally four on each side, but in this species the folds are almost obsolete, being entirely wanting on the left side and reduced to a single slight inward bulging on the right side, bearing internal longitudinal bars. This fold is separated from the dorsal lamina by a broad space without internal longitudinal bars. A similar wide space is present on the left side of the dorsal lamina, and two others on the vertebral edge of the sac, one on each side of the endostyle. These spaces vary in size in individuals. They commonly contain 16 stigmata, but numbers down to 12 were frequent and in one case 10 only were present: only once more than 16 observed, and in that case there were 23. Number of internal longitudinal bars on fold varies from 6 to 9, generally 8 or 9. HERDMAN, p. 330.

In considering the significance of these cases with reference to the origin of Species it is to be remembered that the characters of the branchial sac, the sizes of the transverse vessels, shape of meshes and the number of stigmata they contain are held to be of the first importance for the classification of Ascidiæ; but HERDMAN finds that while they are highly characteristic in some species they are not so in others¹.

II. CYCLOSTOMI.

- *139. **Myxine glutinosa**. In this genus there are normally six pairs of branchial pouches. I am indebted to Professor Weldon for an account of a specimen dissected by him in which there were seven pairs of these pouches. On the left side all the seven pouches were distinct and separate, each having a separate open-

¹ The olfactory tubercle in Ascidiæ may have a different form and position in different individuals of the same species, but the range of variation changes according to the species. *Molgula* was found to be the most constant, *Ascidia virginea* and *A. plebeia* the most variable forms. HERDMAN, *Proc. R. Phys. Soc. Edin.*, vi., p. 267, figs.; also *id.*, *Proc. Lit. Phil. Soc. Liverpool*, xxxviii, p. 313, Pls. i. and ii. Variation respecting the atrial pore will be considered in connexion with Bilateral Repetition.

ing from the œsophagus and a separate aortic arch supplying it. On the right side the sixth and seventh pouches were practically

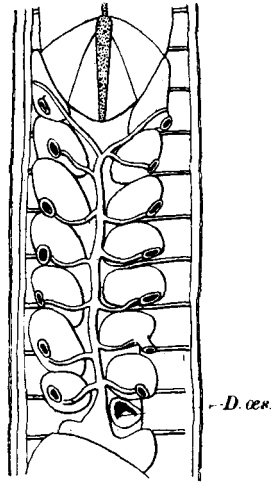


FIG. 27. *Myxine glutinosa*; specimen having seven pairs of branchial sacs. Diagram shewing branchial sacs, heart and aortic arches from the dorsal surface. On the right side the sixth and seventh branchial sacs were partially confluent.

D. œs., ductus œsophageus.

(From a drawing kindly lent by Prof. Weldon.)

confluent though each had a separate œsophageal opening and a separate arch from the aorta. In the drawing, for which I am also indebted to Professor Weldon, the œsophageal openings are not shewn.

- *140. **Bdellostoma.** In this genus the number of branchial sacs is variable, different numbers being found in different species and individual variation also occurring.

The generic name *Heptatrema* was originally given by DUMÉRIL from the presence of seven gill-sacs. In 1834 JOH. MÜLLER, finding that this character is not constant proposed the name *Bdellostoma*. Of three Cape specimens examined by him one had seven gill-sacs on each side, one had six on each side, and one had six on the right side and seven on the left. To these he gave the names *B. heptatrema*, *B. hecatrema* and *B. heterotrema* respectively (*Abh. k. Ak. Wiss. Berlin*, 1834, pp. 66, 67 and 79, Taf. VII.). Further observation has shewn that the number of gill-sacs in the Cape *Bdellostoma* is liable to individual variation, some specimens having six while others have seven. The name *B. cirrhatum* (GÜNTHER, *Cat. Brit. Mus.*, VIII. 1870, p. 511) includes these and the New Zealand specimens. As to the relative frequency of specimens with six or seven pairs or with an asymmetrical arrangement I have no information. A collection lately brought from the Cape by Sedgwick includes one specimen with six pairs and several with seven pairs.

141. **B. polytrema** : single specimen from Chili, badly preserved but apparently having fourteen pairs of gill-openings. GÜNTHER *l. c.*, p. 512.

Specimen having 14 gill-openings on left side and 13 on right. SCHNEIDER, A., *Arch. f. Naturg.*, XLVI. 1880, p. 115 (cp. PUTNAM, *Proc. Bost. N. H. S.*, XVI. 1873, p. 160).

B. bischoffii : single specimen, 10 gill-openings on each side. *ibid.*

Ammocœtes : having eight branchial openings on each side instead of seven, the normal number. The shape of the mouth of this specimen was also abnormal, being described as somewhat square. [No satisfactory description.] EDWARD, THOMAS, *Zoologist*, XVI., p. 6097.

142. In connexion with individual Variation in the number of gill-sacs in Myxinoids it should be borne in mind that in *Petro-myzon* there are normally seven pairs of gill-sacs. The case of the Notidanidæ may also be mentioned in this connexion. Among Selachians the Notidanidæ are peculiar in having a number of gill-slits other than five, and of them *Hexanchus* has six pairs, while *Heptanchus* has seven¹.

III. CERVICAL FISTULÆ AND SUPERNUMERARY AURICLES IN MAMMALS.

Though the evidence of this subject is well known and has often been collected, it may be convenient to give here some abstract of the facts in so far as the phenomena of Variation are illustrated by them. Since cervical fistulæ have been believed to result from the persistence of the embryonic branchial clefts, they may properly be considered in relation to the general question of Variation in the number of gill-slits, while the development of external appendages, perhaps serially homologous with the external ears, directly concerns the subject of Meristic Variation.

Man. The subject has been studied by many observers, especially by ASCHERSON², and by HEUSINGER³, who brought together and abstracted 46 cases, being all that had been described in Man up to 1864. G. FISCHER⁴ gives a full list of the literature of the subject up to 1870, with an analysis of 65 cases. A further paper by HEUSINGER⁵ contains a general account of these structures as they are found in Man and in the domestic animals. Additional cases, together with a general discussion of the subject, especially in relation to fistulæ on the external ears, were given by Sir JAMES

¹ **Balanoglossus.** In five species with which I am acquainted, the number of gill-bars and slits varies in proportion to the size of the body, and as it is not unlikely that these animals continue to grow throughout life, it is probable that the number of branchiæ is always increasing by formation of new gill-slits at the posterior end of the branchial region. The same is probably true of *Amphioxus*.

² ASCHERSON, *De fistulis colli congenitis*, Berlin, 1832.

³ HEUSINGER, *Arch. f. Path. Anat. u. Phys.*, 1864, XXIX.

⁴ FISCHER, G., *Deut. Ztsch. f. Chirurg.*, 1873.

⁵ HEUSINGER, *Deut. Ztsch. f. Thierm.*, 1878.

PAGET¹ in 1878. Lastly, the whole evidence as to cervical fistulæ and the structures associated with them has been fully collected up to 1889 and tabulated by KOSTANECKI and MIELECKI², who also discuss in detail the relations of these abnormalities to the facts of development. The following account is taken from these sources. For figures the reader is referred to the original memoirs.

- *143. Cervical fistulæ are generally known as orifices placed in the region of the neck, leading into a sinus of greater or less extent, varying in size from a mere pit to a duct some inches in length. In the greater number of cases the sinus ends blindly, but in about a third of recorded cases (K. and M.) it passes inwards to open into the pharynx, forming thus a communication between the pharyngeal cavity and the exterior. Such passages are spoken of as *complete* cervical fistulæ, those which have an external but no internal opening being *external incomplete* fistulæ. Besides these there are cases of diverticula from the pharynx or œsophagus which do not reach the exterior, and these are known as *internal incomplete* fistulæ.

Cervical fistulæ are more commonly present on one side only, but in a good many cases they have occurred on both sides. According to Fischer they are more common on the right side than on the left. The following statistics are given by him. 65 persons had 79 fistulæ: 51 unilateral, 14 bilateral: 20 complete, 53 without an opening to the pharynx: of the unilateral cases 33 were on the right and 13 on the left: 34 in males, 30 in females. There was evidence of heredity in 21 cases.

The external opening is very small and may either be on the surface of the skin or elevated on a minute papilla. Sometimes it is covered by a small flap of skin as with a valve, in other cases it is placed as a fissure between two lips. The positions in which the external openings of cervical fistulæ are found are very variable, but in the great majority of cases the opening is close to the middle line in the neighbourhood of the sterno-clavicular articulation, generally from a few lines to an inch above it, on either the inner or the outer border of the sterno-cleido-mastoid muscle. In rarer cases the external opening is placed at the level of the middle of the cricoid cartilage, and is sometimes just behind the angle of the jaw. These positions are not however at all precisely maintained, but vary a good deal in different cases. When the external opening is in the higher situation and the fistula is complete, a sound may then be passed into the pharynx, but when the external opening is low, the duct when present passes upwards covered by skin only, in a straight line so far as the upper limit of the larynx, at which point it turns at a sharp angle upwards and inwards. For this reason it is not possible in such cases to follow the course to the pharynx by means of a sound, but in some of them the presence of an internal opening has been proved by the injection of fluids having colour or taste. The position of the internal openings is also variable, and from the nature of the case has been accurately

¹ PAGET, Sir J., *Trans. Med. Chir. Soc.*, LXI., 1878.

² VON KOSTANECKI und VON MIELECKI, *Arch. f. path. Anat. u. Phys.*, CXX. and CXXI.

determined in comparatively few instances. In a case dissected by NEUHÖFER¹ there was a fistula on each side, the external opening of the right was $\frac{1}{2}$ in. from the middle line and 7 lines above the clavicle, that of the left was 3—4 lines higher and further from the middle line. The right internal opening was on the posterior border of the pharyngo-palatine muscle, behind the cornu of the hyoid near the tonsil, the left internal opening being rather higher than the right. Internal openings of such fistulæ have also been seen on the edge of the arcus pharyngo-palatinus, also in the neighbourhood of the root of the tongue. SEIDEL² gives a case in which there were two fistulæ, the one on the right side in the upper position, and the other in the middle line at about the same level, but whether either of these communicated with the pharynx could not be made out. The twin-brother of the same infant had a single minute fistula.

The ducts of cervical fistulæ are usually of greater calibre than the external openings but they are rarely wider than a fine quill. The walls are tough and the lining epithelium is sometimes flat and sometimes ciliated. The degree to which the walls are sensitive differs in different cases. The external opening is described in several instances as having a reddish colour. In three cases of the presence of branchial fistulæ in female patients, it is recorded that the external openings became inflamed during the menstrual periods.

From the point of view of the naturalist the chief interest of cervical fistulæ arises in connexion with the question of their morphology. Since the time of Ascherson the view has been commonly accepted that these structures arise by persistence of embryonic gill-clefts, and some of the recent writers³ on the subject have gone so far as to apportion the various forms of cervical fistulæ among the several gill-clefts from the first to the fourth, according to the situations of the external openings, giving diagrams shewing the regions occupied by each. As KOSTANECKI and MIELECKI point out, this apportionment is quite arbitrary; for in the development of the neck the external invaginations for all the clefts behind the hyoid arch become included in the sinus cervicalis of Rabl (sinus præcervicalis of His), which is eventually closed by the growth of the opercular process from the hyoid arch. The external opening of a cervical fistula may thus represent a part of the sinus cervicalis still left open, but it cannot on the ground of its position be referred to any gill-cleft in particular. Such reference could only be properly made on the ground of the position of the internal opening and the course of the duct in relation to structures whose relation to the visceral clefts is known. Moreover owing to the way in which the 3rd and 4th clefts are shifted inwards by the formation of the sinus cervicalis, Kostanecki and Mielecki consider that they are practically excluded. The same authors after an analysis of the cases in which the position of the internal opening has been properly ascertained, come to the conclusion that in all these it falls within the region of the 2nd visceral sac

¹ NEUHÖFER, M., *Ueb. d. angeb. Halsfistel*, Inaug. Diss., Munich, 1847.

² SEIDEL, J., *De fist. colli congen.*, Inaug. Diss., Breslau, 1863.

³ SUTTON, J. BLAND, *Lancet*, 1888, p. 308; CUSSET, *Étude sur l'appareil branchial*, &c., Paris, 1887.

(hyo-branchial). Besides they point out that the evidence in the few cases in which the course of the duct has been traced, shewed that it passed between the external and internal carotids. In their judgment, therefore, cervical fistulæ are all to be referred to the second (hyo-branchial) cleft.

Next it is to be remembered that according to many observers (especially HIS) there is at no period a complete connexion between the outer gill-clefts and the evagination from the pharynx or branchial sacs, but the membrane separating these chambers is stated by them never to be broken down. If this account is accepted, it is, as KOSTANECKI and MIELECKI have said, necessary to suppose that in the case of any complete cervical fistula a communication between the exterior and the pharynx has arisen by some abnormal occurrence. This is illustrated by reference to the normal condition of the first or hyo-mandibular cleft. Here the auditory meatus represents an external incomplete fistula, and the Eustachian tube an internal incomplete fistula, the two being separated by the tympanic membrane. In a single case given by VIRCHOW¹ a complete passage existed congenitally in this position, together with great abnormality in position and form of the external ear.

From the evidence it may thus on the whole be concluded that incomplete external fistulæ result from imperfect closure of the sinus cervicalis, and that incomplete internal fistulæ may arise by persistence of one of the branchial sacs, but it is doubtful whether many cases of the latter properly belong to the category of branchial fistulæ at all.

Supernumerary Auricles.

144. Abnormal appendages attached to the neck have been described by several observers, and by those who have discussed the subject of cervical fistulæ some account of these appendages is generally given. In the neighbourhood of the external ears, especially near the anti-tragus, such structures having the form of small warts or flaps of skin are not very uncommon. Their presence is generally associated with deformity of the external ear, and often with what are known as "aural fistulæ²." In the region of the neck, supernumerary auricles

¹ VIRCHOW, *Arch. path. Anat. u. Phys.*, 1865, xxxii.

² *Aural fistulæ* are spoken of by many writers as being of the same nature as cervical or branchial fistulæ. They are blind ducts or pits, opening on some part of the external ear and are nearly always associated with other abnormalities either in the form of the ear or defective hearing, &c. (SCHMITZ, *De fist. colli congen.*, Inaug. Diss., Halle, 1873 [not seen, W. B.]; URBANTSCHITSCH, *Monatsch. f. Ohrenh.*, 1877, transl. *Edin. Med. Jour.*, xxiii. 1878, p. 690.) They may be either unilateral or on both sides of the body. SIR JAMES PAGET (*Trans. Med. Chir. Soc.*, lxi., p. 41) described the occurrence of such fistulæ in the ears of several members of a family, many of whom were affected with deafness. The supposed connexion of these fistulæ with cervical fistulæ was in this case suggested by the fact that several cases of actual cervical fistulæ occurred in the same family, several of its members having both cervical and aural fistulæ. From the evidence of the not infrequent association of the two kinds of malformation most writers (PAGET, URBANTSCHITSCH, &c.) consider that the aural fistulæ must be branchial in origin and may be taken to represent the first (hyo-mandibular) cleft.

KOSTANECKI and MIELECKI (*l. c.*), following HIS, point out that since in no case has an aural fistula ever been known to communicate with the auditory meatus or tympanic cavity, this belief is unsupported; and in addition, that from the mode of development of the external ear from a number of tubercles, it is

are much rarer, but in several instances they have attained a considerable development. Of this class of variation the following well-known case is one of the most remarkable.

- *145. A healthy female infant was brought to Guy's Hospital in 1851 on account of two projecting growths about the middle of the lateral cervical regions. The growths were not removed until February 1858, when they were found to have increased slightly. They were situated over about the centre of the sterno-cleido-mastoid muscles. To the touch they resembled the tissue of the lobe of the auricle, and they contained within them a firm resisting nucleus like the cartilage of the same organ. They were also covered with peculiarly delicate, soft, downy hairs, like the lobe of the ear. They were excised without difficulty. Each was supplied with a small artery. They appeared to be intimately associated with the fibres of the platysma myoides, not dipping deeper than this structure, and to be entirely cutaneous appendages. (Fig. 28.)



FIG. 28. Child having a well-developed supernumerary auricle on each side of the neck (from BIRKETT).

A vertical section was made in the long axis of each growth; and the tissues of the lobe and of the fibro-cartilage of the auricle were clearly distinguished. The shape of the fibro-cartilage resembled more or less closely in parts, the outline of the proper auricle, and its tissues were the same. BIRKETT, J., *Trans. Path. Soc. Lond.*, ix., 1858, p. 448, fig.¹.

sufficient to suppose that aural fistulæ arise by the imperfect union of these tubercles. The fact, however, that these various defects in development of the branchial apparatus and its derivatives are frequently associated together is well established. As indicating the frequency of association with disease of the ear, Urbantschitsch mentions that in 2000 aural cases, 12 instances of aural fistulæ were seen. The same author gives a remarkable case of the occurrence of aural fistula on the *right side only* in many members of the same family with other important particulars (*l. c.*).

¹ In *Lancet*, 1858, ii. p. 399 (quoting HARVEY), and in a paper by VIRCHOW (quoting WILDE), *Arch. path. Anat. Phys.*, 1864, xxx. p. 225, reference is made to a case of CASSEBOHM, *Tract. sextus, de aure monstri hum.*, Norimb., 1684, pp. 36 *et seqq.*, describing a child with "four ears." On referring to the original however it appears that this was merely a double monster, having two incomplete heads, and thus bears no analogy with the present examples.

Several cases analogous to the above, though differing in the extent of the development, are on record¹. KOSTANECKI and MIELECKI (*l. c.*), who give references to the literature of the subject, consider together with VIRCHOW and others, that there is no doubt that these supernumerary auricles may properly be regarded as "heterotopic" partial repetitions of the external ears. According to a view which has been held by the majority of writers on the subject, and which is in part alternative to that given above, it is suggested that the cartilages contained in these appendages are in reality parts of one or other of the usually undeveloped branchial arches behind the hyoid. As against this suggestion it is to be remembered that in the subsequent development of the neck these arches are pushed in far from the surface, whereas the cartilages in question are always superficial. The usual histology of these bodies is in favour of the view that they are repetitions of the ear-cartilages, but on the other hand a specimen of cervical auricle in Mus. Coll. Surg. (No. 373, *c*) contains not only cartilage but also a small bone of complex form. But whether or not any part of such cervical auricles truly represents any part of the gill-bars, it is clear that these external projections having the structure of the ear, considered from the point of view of Variation must be regarded as partial repetitions of the ears, and there is a considerable probability that they stand to the sinus cervicalis in a relation similar to that which the normal external ear bears to the hyo-mandibular cleft, being according to the terminology here proposed, examples of repetition by forward Homœosis.

In this connexion the question of correlation between supernumerary auricles of the neck and cervical fistulæ is especially important. If it is true that such auricles are repetitions of the ears, it might, on the analogy of other cases of repetition, be expected that they would usually be found bounding the external openings of fistulæ. As a matter of fact they have several times been found in such a position, but the connexion between these two variations is by no means a close one, for cervical fistulæ are not as a rule accompanied by cervical auricles, nor are cervical auricles generally associated with cervical fistulæ, such collocation being on the whole exceptional. It should also be mentioned that in a few cases small cartilaginous or bony structures have been found imbedded in the neighbourhood of cervical fistulæ, but that similar structures have also occurred independently of any fistula².

In many domestic animals both cervical fistulæ and auricles are well known and have been described by Heusinger³ from whom the following account is chiefly taken.

146. **Fig.** Cervical auricles are not uncommon and have been referred

¹ A figure is given by SUTTON, J. B., in *Ill. Med. News*, 1889 (repeated in "*Evolution and Disease*," by the same author 1890, p. 83), representing a large supernumerary auricle on the right side of the neck of a girl. The structure is represented as helicoid in form, closely resembling the normal ear. It is unfortunate that no description of this specimen is given: in the absence of such description this quite unprecedented case cannot be accepted without reserve.

² Dermoids of many kinds occurring in the cervical region of Man and other animals are by many writers considered to arise by modification of tissues occluded from the walls of the branchial clefts.

³ HEUSINGER, *Deut. Arch. f. Thiermed.*, 1876, II.

to as distinguishing particular local breeds. They are generally paired structures. The following case is exceptional in the fact that the auricle was present on the left only, and that it was associated with an opening possibly of a cervical fistula. A pig having a single appendage about 7 cm. long attached under the lower jaw on the left, is described by Eudes-Deslongchamps¹. It contained a stalk of cartilage stated to have resembled the cartilage of the ear. To this on either side was attached a small muscle. Unfortunately the appendage had been cut off close to the skin. A small opening (*pertuis*) was present on the skin near the appendage, and from this opening a small brush or tuft of bristles protruded.

Fistulæ in the neck of swine are well known as giving rise to a disease called *weisse Borste* in Germany (Fr. *la Soie* or *poil piqué*) from the fact that certain white bristles are found at the opening of the duct. In the popular fancy it is supposed that the bristles themselves bore the perforation, but according to Zündel² they are congenital and often bilateral. Heusinger agrees with Zündel in regarding such openings as branchial fistulæ.

147. **Sheep and Goats.** Cervical fistulæ unknown, but appendages on the neck common. The sheep of the Wilster marshes are described³ as having the neck bare of wool, and an appearance as of a fur-collar. Above the collar and below the pharynx they have a pair of appendages about the size of an acorn. Such appendages are said to be not uncommon in Merinos⁴. Among the Kalmuck and Kirghiz sheep and goats such auricles are said by Pallas⁵ to be common. In many foreign races of goats these auricles seem to be a constant character. In position they may vary from the angle of the jaw to the middle of the neck. The length is usually about 3 in. but they are recorded as reaching 15 cm. Figures of goats having such auricles are given by Sutton⁶. The anatomy of one of these bodies is described by Goubaux⁷, and it is mentioned that a plate of cartilage was found in the interior. A similar cartilage was found by Stewart⁸ together with striped muscular fibre. Goubaux gives a case of two she-goats on a farm, one having cervical appendages, the other having none. Each gave birth to a pair of kids at the same time. Each pair was a male and female, and in the one the male only had the appendages and in the other the female only. The characters of the father of these kids were not known.

- Ox.** Neither cervical fistulæ nor auricles known.
148. **Horse.** Cervical auricles unknown. Fistulæ (in the position considered by Heusinger to indicate the first branchial cleft) are common and are recognized by their action in soiling the hair near the external opening.

RECAPITULATION. The evidence as a whole goes to shew that structures, sometimes of large size, having several essential features of the external ear, that may in fact be fairly spoken of as repetitions of the ear, may by Homœotic Variation appear on the neck of Man and other animals: further, that these repetitions have been known to occur at the openings of cervical fistulæ, suggesting a comparison with the relation of the external ear to the hyo-mandibular cleft, but that such a relation to cervical fistulæ is exceptional.

¹ *Mém. Soc. Linn. de Norm.*, 1842, vii. p. 41, Pl. iv. fig. 3.

² *Deut. Arch. f. Thierm.*, i. 1875, p. 175.

³ VIBORG, *Samtl. Vet.-Afsandl.*, i. p. 148 [Heusinger].

⁴ SCHMALZ, *Thierveredlungskunde*, p. 223 [Heusinger].

⁵ *Spicileg. Zool.*, xi. p. 172 (two figures).

⁶ SUTTON, J. B., *Evolution and Disease*, pp. 84 and 85.

⁷ GOUBAUX, *Rec. de Méd. Vétér.*, Ser. 3, ix. p. 335.

⁸ Figured by SUTTON, *l. c.*, p. 87.